



► **Research & Development**  
Lichen Sclerosus  
Continued ..... pg 2



► **Test Announcement**  
Tests now available in the clinical  
laboratory  
Full Article ..... pg 2



► **Journal Watch**  
Summaries of recent topical  
publications in the medical literature  
Full Article ..... pgs 5

# The Laboratorian<sup>SM</sup>

## Lichen Sclerosus



Author:  
HUMIGEN LLC, the Institute for Genetic Immunology

### Overview

Lichen Sclerosus is a skin condition wherein patches of smooth, shiny, distinctly white skin appear that have a thin, papery, porcelain-like appearance. While there may be no additional symptoms, these patches may grow into areas that have a wrinkled, blotchy appearance; there may be severe itching, tenderness, easy bruising or tearing and in severe cases, this tearing may lead to bleeding, blistering or ulceration. It is thought to be an inflammatory disorder and not mediated by any infectious agent.

Lichen Sclerosus (LS) can affect anyone, and while it is most common in post-menopausal women, young girls, boys and men are also afflicted, but these are much less common. In women and girls, the most common site of LS is the vulval-anal region, while in men and boys the condition generally affects the foreskin. Here, in severe cases, loss of elasticity in this tissue can require circumcision. In both girls and boys, the condition may resolve spontaneously around puberty.

While the cause of LS is presently undefined, its etiology suggests that estradiol may protect women of child-bearing age. There is also reasonable evidence that LS has an autoimmune component. Neither of these two observations however, indicates any particular triggering event; nonetheless, previous skin damage at an LS site has been posited as important in this regard.

LS can occur on skin outside the anogenital area (extragenital LS) and here, it may be treated by observation. Anogenital symptoms however are usually treated to diminish itching and the consequent risk of infection. Topical glucocorticoids applied over several weeks is usually the first approach and if this is unsuccessful, more powerful immunomodulators may be used.

### Common Features and Presentation

LS is defined as a chronic, inflammatory dermatosis, resulting in white plaques with epidermal atrophy. It is relatively common, although the distribution of patients between dermatologists, gynecologists, urologists and other clinical disciplines makes it hard to determine the true frequency. In female patients, genital LS has two peaks of presentation, prepubertal and post-menopausal. A similar bimodal onset is observed in males.

As previously stated, LS presents genitally and extragenitally. While LS is the common term for all aspects of the disease, it may be described as "Lichen sclerosus et atrophicus" in a dermatological context, or "Balinitis xerotica obliterans" if the head of the penis is involved. There are few data that suggest an association with malignant disease and precise risks (such as radiotherapy or HPV) are undefined. Genital presentation (vulval and penile) outnumber extragenital presentations by 5:1, and female patients outnumber male by 10:1. Taken together, this means that LS is primarily a condition afflicting older women in their anogenital region. Formal diagnoses are almost always histological.

In certain cases, where there is a poor response to topical glucocorticoid treatment, it may be difficult to differentiate between LS and the closely-related Lichen Planus (LP) and these "overlap syndrome" patients are the ones who are at risk of squamous cell hyperplasia.

**The Adult Female Patient:** This is the most common patient. Her typical LS regions will be "porcelain-white" and associated with redness and bruising. She will most likely be experiencing severe itching and may have introduced tears through scratching of the thinned skin, leading to pain and possible opportunistic infection. LS regions never affect mucosal tissue so, unlike LP, it is never

found inside the vagina or on the cervix. Characteristic sites include the perineum, the major and minor labia and the clitoris and clitoral hood. Since LS is intrinsically a scarring condition, loss of elasticity and even sealing of the clitoral hood may occur. Scarring at the entrance to the vagina can make intercourse difficult and painful, as can fissures arising in the thinned skin. Perianal LS occurs in 30% of cases and again, fissures may result in difficult bowel movements and infection.

**The Juvenile Female Patient:** The regions affected in juveniles are very similar to those in adult females. However, bruising can be very pronounced and perianal fissures may be more common, leading to patients presenting with constipation as the primary symptom.

**The Adult Male Patient:** Perianal LS is rarely found in males. LS is almost completely confined to the penis, particularly the foreskin prepuce and the glans, with LS regions on the shaft being rare. The scarring nature of LS often leads to presentation associated with foreskin tightening and consequently painful intercourse and erection. More so than in females, changes in urination or simple visual awareness of LS may lead to initial presentation; itching and bruising are rare in male LS patients.

**The Juvenile Male Patient:** Most frequently, juvenile males present with a severely constricted and non-retractable foreskin through LS-related scarring at the prepuce. This can often be sufficient to prevent efficient urine egress and so lead to "ballooning" and pain at urination. As in adult males, perianal LS is very rare.

### Extragenital LS in adult and Juvenile Males and Females

Again, extragenital LS is most frequently seen in adult females, with the upper body, armpits, buttocks and inner thighs as common sites. The lesions are the typical LS porcelain-white plaques, with regions of bruising, similar to those of genital LS; blistering may be present.

### Confirmatory Histological Examination

This is not always necessary, unless there is reason to suspect metaplastic or neoplastic changes (for example, erythema, wart-like lesions and/or hyperkeratosis that does not resolve with glucocorticoid treatment). Histological analyses invariably show significant leukocytic infiltration.

### Evidence for an Autoimmune Component

The etiology of LS is unclear, but autoimmune mechanisms are being called upon more frequently. Associations with other autoimmune diseases have been noted (in particular, Thyroid Disease), there is a recognized tissue-specific autoantibody profile and MHC class-II associations, all indicative of an autoimmune background. This is supported by the presence of circulating extracellular matrix proteins, and basement membrane zone protein bp180 may be emerging as important at both T-cell and B-cell levels.

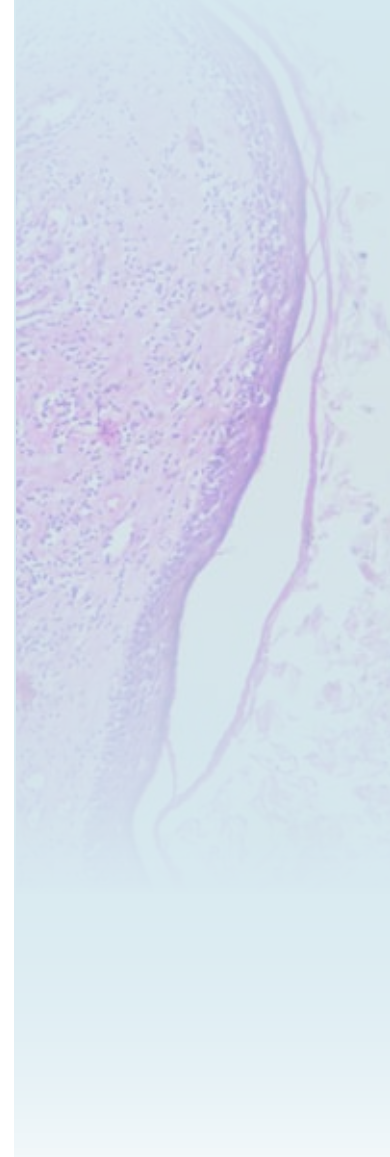
### Relationship with Malignant Disease

It may be quite difficult to navigate the literature regarding LS and malignant disease, in order to separate descriptions of patients with both conditions, and those that address whether LS confers an additional risk. A significant literature exists regarding the role of papilloma viruses in

Continued.....pg 2

### WHAT'S INSIDE ►►

P2	Lichen Sclerosus
P3	Recent Publications
P3	e-quiz
P3	Q&A
P2	New Tests Announcement
P5	Journal Watch
P6	Classified Ad



warty (verrucous) malignancies, but the major malignancy risk appears to be Squamous Cell Carcinoma (SCC). In younger women, there is a clearly-defined risk of HPV-associated vulvar carcinoma in LS patients, which may have its origins in normal sexual transmission of the virus and less with LS *per se*; SCC in older women may be more associated with the scarring dermatosis associated with PS proper. Nonetheless, while the risk of SCC in LS patients is small (approximately 5% and then only in anogenital LS), a majority of these cases have been confirmed histologically to have an LS background. In male patients, a histological background of LS has been suggested to accompany up to 40% of penile carcinoma cases and again, the role of HPV in malignant initiation is still debated.

### Patient Management

There is no cure for LS. While some juvenile cases and extragenital cases may spontaneously resolve, the major patient type - postmenopausal females - are candidates only for symptom management at this point. A number of support groups and on-line self-help fora exist.

In male patients with a constricted prepuce, topical glucocorticoids are effective at reducing prepuce tightness and the need for circumcision, which remains as an option, particularly if scarring has taken place.

In adult female patients with anogenital LS, glucocorticoid application is effective in a majority of cases. The recurrent flares in those who fail to respond can be managed with a change of steroid and/or more frequent application. Administration of systemic glucocorticoids is almost never used, but nonetheless local effects of long-term glucocorticoid application, such as enhanced skin-thinning, may also need to be managed. In general, extragenital LS is not so responsive to glucocorticoids as genital LS.

More recently, use of calcineurin inhibitors have been gaining popularity, partly in recognition of the role of T-cells in the underlying pathology, but anecdotal side effects, ranging from stinging on application to cases of SCC, do not support the use of these materials as first-line options.

### Conclusion

Lichen Sclerosus continues to be a significant issue. The condition afflicts mainly post-menopausal women, but also adult males and juveniles of either sex. The condition is largely restricted to the anogenital region in females, and the penis in males, but extragenital lesions do occur. There are indications, but no clear evidence, of LS predisposing to malignant disease, and SCC in particular, although co-infection with HPV may be problematic for certain patients. There is no cure and the mechanisms leading to disease development are undefined; therefore, there is no present route for the physician to take for straightforward diagnosis of this debilitating condition.

- This article called upon information from Internet-based lay-persons, medical sites, the British Association of Dermatologists' guidelines for the management of lichen sclerosus, published in 2010, [Neill SM et al, Br J Dermatol, vol. 163, p672-682, 2010] and "Pubmed" searches using the terms "lichen sclerosus", "lichen sclerosus AND autoimmune" and "lichen sclerosus AND malignan". Readers are referred to the original sources for references to the primary scientific and medical literature.



## Medical Diagnostic Laboratories, L.L.C.

### New Tests Released In 2012

In the last year, MDL was proud to release many new and innovative tests. In order to take full advantage of the tests available, clients are encouraged to update their Electronic Medical Record (EMR) systems with the information below:

Test No.	Test Name	Specimen Collection Platform	Date
436	Heartland virus (Phlebovirus) by Real-time PCR	Whole blood (ACD Solution A tube) or tick.	11/2012
370	<i>Giardia lamblia</i> by Real-Time PCR	Validated on <b>OneSwab</b> ® for intestinal pathogens testing of loose stool specimens.	10/10/12
369	<i>Acinetobacter baumannii</i> by Real-Time PCR	<b>OneSwab</b> ® & <b>UroSwab</b> ® & <b>NasoSwab</b> ®	10/10/12
150	<i>Helicobacter pylori</i> by Real-Time PCR	Validated on <b>OneSwab</b> ® for intestinal pathogens testing of loose stool specimens.	9/6/12
105	<i>Chlamydia trachomatis</i> by Real-Time PCR ( <b>Reflex to Azithromycin Resistance</b> )	Reflex testing at no additional cost on <b>OneSwab</b> ® & <b>UroSwab</b> ®	9/4/2012
167 & 105	<i>N. gonorrhoeae</i> * & <i>C. trachomatis</i> * by Real-Time PCR (*Reflex to Antibiotic Resistance by Bio-Plex Analysis) (* Reflex to Azithromycin Resistance by Pyrosequencing)	<b>UroSwab</b> ® for females not candidates for pelvic exam	8/31/2012
190	HPV-16 and HPV-18 by Multiplex Real-Time PCR	<b>OneSwab</b> ® & <b>UroSwab</b> ®	9/2012
366	<b>Skin &amp; Soft Tissue Infections (SSTI) Panel</b> [ <i>B. fragilis</i> , <i>E. faecalis</i> , <i>E. coli</i> , GAS, GBS, <i>Klebsiella</i> species, Prevotella Groups 1 & 2, <i>P. mirabilis</i> , <i>P. aeruginosa</i> , <i>S. aureus</i> , MRSA, Community Associated MRSA (CA-MRSA)]	<b>OneSwab</b> ®	7/25/2012
367	<b>Skin &amp; Soft Tissue Infections (SSTI) Panel Antibiotic Resistance</b> [ <i>Enterococcus faecalis</i> , <i>E. coli</i> , GAS, GBS, <i>Klebsiella</i> species, <i>P. mirabilis</i> , <i>P. aeruginosa</i> , CA-MRSA: amoxicillin-clavulanic acid, ampicillin (for <i>E. faecalis</i> ), cephalothin (cephalexin), clindamycin, doxycycline, trimethoprim-sulfamethoxazole, ciprofloxacin, cefepime, piperacillin-tazobactam, imipenem, gentamicin] ** (153, 141, 1112, 127, 172, 146, 174, or 118 Req.)	<b>OneSwab</b> ®	7/25/2012
182	<b>Aerobic Vaginitis (AV) Panel by Real-Time PCR</b> (GBS, <i>S. aureus</i> , <i>E. coli</i> , <i>E. faecalis</i> )	<b>OneSwab</b> ®	4/2/2012
187	<b>Sexually Transmitted Disease (STD) Screen by Real-Time PCR</b> ( <i>C. trachomatis</i> , <i>N. gonorrhoeae</i> , <i>T. vaginalis</i> , HPV, <i>M. genitalium</i> , <i>M. hominis</i> , <i>U. ureaplasma</i> )	<b>OneSwab</b> ®	4/2/2012
111	<i>Trichomonas vaginalis</i> by Real-Time PCR (Reflex to Metronidazole resistance)	Reflex testing at no additional cost on <b>OneSwab</b> ® and <b>UroSwab</b> ®	3/2012
	<b>SEMEN PATHOGEN DETECTION: by Real-Time PCR unless otherwise specified</b>	Semen (non-additive specimen collection cup or transfer vial)	3/2012
	105 <input type="checkbox"/> <i>Chlamydia trachomatis</i> 141 <input type="checkbox"/> <i>Escherichia coli</i> 153 <input type="checkbox"/> <i>Enterococcus faecalis</i> (Reflex to vancomycin-resistant vanA & vanB) 1112 <input type="checkbox"/> Group A Streptococcus 127 <input type="checkbox"/> Group B Streptococcus (GBS) 137 <input type="checkbox"/> Group B Streptococcus (GBS) Antibiotic Resistance by PCR** (#127 Req.) Only check if patient is penicillin-allergic and erythromycin/clindamycin resistance determination is required for alternate treatment 172 <input type="checkbox"/> <i>Klebsiella</i> species (Reflex to Speciation by Pyrosequencing) 167 <input type="checkbox"/> <i>Neisseria gonorrhoeae</i> (Reflex to Antibiotic Resistance by Bio-Plex Analysis) 109 <input type="checkbox"/> <i>N. gonorrhoeae</i> * & <i>C. trachomatis</i> 146 <input type="checkbox"/> <i>Proteus mirabilis</i> 183 <input type="checkbox"/> Reproductive Pathogens Antibiotic Resistance [ <i>Enterococcus faecalis</i> , <i>E. coli</i> , <i>Klebsiella</i> species, <i>Proteus mirabilis</i> : ampicillin, amoxicillin-clavulanic acid, cephalothin (cephalexin), ciprofloxacin, doxycycline, moxifloxacin]** (141, 153, 172, or 146 Req.) 1118 <input type="checkbox"/> <i>Staphylococcus aureus</i> with methicillin resistance (MRSA) by Conventional PCR 1119 <input type="checkbox"/> Panton-Valentine Leukocidin (PVL) DNA** (Type IV + #1118 Req.) [Community Associated MRSA = Type IV MRSA+ and PVL+] 178 <input type="checkbox"/> <i>Ureaplasma parvum</i> 320 <input type="checkbox"/> <i>Ureaplasma urealyticum</i>		

\*\* This test can only be performed when the test in parenthesis is positive. All tests performed will be billed.

- True of False.** Lichen Sclerosus (LS) is mediated by an infectious process.
- LS affects the following groups:
 

A. Post-menopausal women	C. Boys and men
B. Young girls	D. All of the above
- \_\_\_\_\_ is believed to play a protective role against LS in women of child-bearing age.
- True of False.** Although in women there appears to be a bimodal onset, this is NOT the case as observed in males.
- LS may be observed by practitioners in which of the following medical specialties?
 

A. Dermatologists	C. Gynecologists
B. Urologists	D. All of the above

For results to the electronic Epidemiology Quiz, please visit [www.mdlab.com](http://www.mdlab.com) and click on the e-Quiz link.

## Quality Assurance Q&A

### Question:

I received the results from testing I ordered for a patient. The tests were negative so I would like to request some additional testing. How do I do this?

### Answer:

Testing can be added if the specimen volume permits and it is within an allowable time period from specimen collection. For our swab platforms **OneSwab**<sup>®</sup>, **UroSwab**<sup>®</sup>, and **NasoSwab**<sup>®</sup> test addition requests can typically be honored up to 30 days from receipt of the specimen. For other specimen types, it is best to contact our Client Services Department toll free at 877.269.0090. All test addition requests MUST be received in writing on either a Test Addition Request Form, office stationary, or on a script. These requests should be faxed to MDL's QA/QC Department at 609.570.1020.

If you have a question you would like addressed in future issues, please email your question(s) to [QAQA@mdlab.com](mailto:QAQA@mdlab.com)

## RECENT PUBLICATIONS



### MDL: Research & Development Peer-Reviewed Papers:

- Stemmer SM, Adelson ME, Trama JP, Dorak MT, and Mordechai E. 2012. Detection Rates of *Trichomonas vaginalis*, in Different Age Groups, Using Real-Time Polymerase Chain Reaction. *J Low Genit Tract Dis.* 16(4):352-357.



### Oncoveda Cancer Research Center™: Research & Development Peer-Reviewed Papers:

- Huang L, et al. 2012. CIP2A Protein Expression in High-Grade, High-Stage Invasive Bladder Transitional Cell Carcinoma. *Cancer Medicine, In press.*
- Scher M., et al. 2012. Detecting DNA Methylation of the BCL2, CDKN2A, and NID2 Genes in Urine Using a Nested Methylation-Specific PCR Assay to Predict Bladder Cancer. *J Urol, In Press.*

### Abstracts:

- Huang L, Adelson ME, Mordechai E, Trama J. Cancerous Inhibitor of PP2A (CIP2A) Expression in Bladder Cancer. American Association for Cancer Research (AACR), Chicago, IL. March 31-April 4, 2012.



### Femeris Women's Health Research Center™: Research & Development Peer-Reviewed Papers:

- Hilbert DW, Paulish-Miller TE, Tan CK, Carey AJ, Ulett GG, Mordechai E, Adelson ME, Gygax SE, and Trama JP. 2012. Clinical *Escherichia coli* isolates utilize alpha-hemolysin to inhibit in vitro epithelial cytokine production. *Microbes Infect.* 14(7-8):628-38.
- Chadwick SG, Hart CE, Mordechai E, Adelson ME, Gygax SE. 2012. Staphylococcal Cassette Chromosome mec type and antibiotic susceptibility profiles of vaginal and non-vaginal MRSA clinical isolates. *Diagn Microbiol Infect Dis.* 74(2):210-2.

- Balashov S, Mordechai E, Adelson ME, Gygax SE. 2012. Multiplex Bead Suspension Array for Screening *Neisseria gonorrhoeae* antibiotic resistance genetic determinants in non-cultured clinical samples. *J Mol Diagn, In press.*

- Flowers S, Barker K, Berkow E, Toner G, Chadwick S, Gygax SE, Morschhäuser J, Rogers P. 2012. Gain-of-Function mutations in UPC2 are a frequent cause of ERG11 upregulation in azole-resistant clinical isolates of *Candida albicans*. *Eukaryot Cell, In press.*




### Venenum Biodesign Peer-Reviewed Papers:

- Gallo-Ebert C, McCourt P, Donigan M, Villasmil ML, Chen WW, Pandya D, Romano D, Franco J, Chadwick S, Gygax SE, Nickels JT Jr. 2012. Arv1 lipid transporter function is conserved between pathogenic and nonpathogenic fungi. *Fungal Genet Biol.* 49(2):101-13.

### Abstracts:

- Beasley JR, Malone J, O'Brien L, Sieber McMaster E, Shi D, Xu X, Nawoschik S, Pham Q, Webb M. Discovery of the GPBAR1 (TGR5) Agonists from a 1536-well UHTS of the ECLiPS Compound Collection. 1<sup>st</sup> Annual Conference & Exhibition for the Society of Laboratory Automation & Screening (SLAS 2012), San Diego, CA. February 4-8, 2012.
- Stroke IL, Hilbert DW, Letourneau JJ, Paulish-Miller T, Quintero JG, Sabalski JE. Identification and Characterization of small molecules targeting *Clostridium difficile*. 1<sup>st</sup> Annual Conference & Exhibition for the Society of Laboratory Automation & Screening (SLAS 2012), San Diego, CA. February 4-8, 2012.
- Stroke IL, Miller TE, Letourneau JJ, Mordechai E., Adelson ME, Gygax SE, Hilbert DW. High-throughput screening to identify compounds that inhibit *Bacillus subtilis* sporulation. 112<sup>th</sup> General Meeting of the American Society for Microbiology (ASM), San Francisco, CA. June 16-19, 2012.





## Specimen Labeling Policy...

The College of American Pathologists (CAP) guidelines state, that all primary clinical specimen containers be labeled with two patient identifiers at the time of specimen collection.

### GEN.40491 Specimen Labeling Phase II

*Primary specimen containers are labeled by at least 2 identifiers.*

NOTE: All primary specimen containers must be labeled with 2 identifiers at the time of collection. Submitted slides may be labeled with a single identifier, but two identifiers are preferred. Examples of acceptable identifiers include but are not limited to: patient name, date of birth, hospital number, social security number, requisition number, accession number, unique random number. The 'primary' specimen container is the innermost container received by the laboratory that actually holds the specimen. It is good laboratory practice to use two identifiers.

### Effective November 26, 2012...

- We will require that all specimen containers be labeled at the time of specimen collection with two patient identifiers. These identifiers must correspond to information provided on the test requisition form or accompanying documents.
- As of November 26, 2012, we will begin to note on result reports if a specimen is received without the required two patient identifiers

<b>Preferred first identifier</b>	Patient's first & last name
<b>Preferred second identifier</b>	Patient date of birth
<b>Other acceptable identifiers</b>	<ul style="list-style-type: none"> <li>• Social security number</li> <li>• Requisition number</li> <li>• Patient Identification number</li> <li>• Medical record number</li> <li>• Accession number</li> <li>• Unique random number</li> </ul>
<b>Additional desirable information</b>	<ul style="list-style-type: none"> <li>• Date of collection</li> <li>• Time of collection</li> <li>• Specimen type</li> <li>• Specimen source</li> </ul>

Sincerely,  
MEDICAL DIAGNOSTIC LABORATORIES, L.L.C.

Kelly D. Smith  
Director of Quality Control



## Diagnostic usefulness of dermatoscopy in differentiating lichen sclerosis et atrophicus from morphea

Garrido-Rios AA, Alvarez-Garrido H, Sanz-Munoz C, Aragoneses- Fraile H, Manchado-Lopez P, Miranda-Romero A. 2009. Dermoscopy of extragenital lichen sclerosis. *Arch Dermatol*, 145:1468.

Campione E, Paterno EJ, Diluvio L, Orlandi A, Bianchi L, Chimenti S. 2009. Localized morphea treated with imiquimod 5% and dermoscopic assessment of effectiveness. *J Dermatol Treat* 20:10-3.

Given the challenge of differentiating lichen sclerosis et atrophicus (LS) from morphea, especially in extragenital regions, the authors examined the utility of dermatoscopy as a noninvasive, inexpensive and simple diagnostic tool. LS and morphea lesions were examined using dermatoscopy. A cross-sectional study of 18 patients with biopsy-proven LS and 21 patients with biopsy-proven morphea were included. Statistical significance was evaluated by the Chi-square test.

In this study, the authors found statistically significant differences in the appearance of comedo-like openings ( $p=0.006$ ) and whitish patches ( $p=0.038$ ) in LS, whereas the incidence of fibrotic beams was shown to be higher ( $p=0.038$ ) in the morphea group. These results validate previous independent findings where the comedo-like openings and whitish patches were noted in a LS cohort (Garrido-Rios) while fibrotic beams were observed in morphea (Campione). The incidence of pigment network like structures and linear branching were not different. While the incidence was low, comma-like vessels, hairpin vessels and dotted vessels were only observed in the LS group. This is one of very few reports where these three distinct observations were examined in one study in both LS and morphea.

## The potential role of dendritic cells and TLR activation in initiating Lichen Sclerosis

Guiducci C, Tripodo C, Gong M, Sangaletti S, Colombo MP, Coffman RL, Barrat FJ. 2010. Autoimmune skin inflammation is dependent on plasmacytoid dendritic cell activation by nucleic acids via TLR7 and TLR9. *J Exp Med* 207(13):2931-42.

Wenzel J, Tüting T. 2008. An IFN-associated cytotoxic cellular immune response against viral, self-, or tumor antigens is a common pathogenetic feature in "interface dermatitis". *J Invest Dermatol*. 128(10):2392-402.

In the study referenced above, Campione et. al. report on morphea treated with imiquimod 5%. Imiquimod induces high levels of  $\alpha/\beta$ -interferons, and is used in the treatment of a variety of "interface dermatitis" (ID) conditions. The fact that interferons can be implicated in both the pathogenesis and treatment of these conditions highlights the divergent nature of plasmacytoid dendritic cells (pDC), which are the principal producers of this cytokine. Guiducci et. al. examined the activation of toll-like receptor (TLR) 7 and 9 in mouse models of autoimmune skin inflammation. TLR7 and TLR9 bind microbial RNA and/or DNA, are highly expressed on pDC. Stimulation through these receptors has been shown by others to induce production of large amounts of the type-I interferons, Interferon- $\alpha$  and  $\beta$ .

In this article, the authors use tape stripping to administer TLR7 or TLR9 agonists directly to the skin as a method to model inflammation. This treatment resulted in rapid infiltration and localization of pDC to the skin, production of type-I IFNs and activation of IFN-responsive genes. This cascade led to the recruitment of neutrophils, production of IL-1 and TNF, and formation of acute and transient lesions. Cytokine production was markedly reduced in MyD88-deficient mice with deficient TLR signaling, suggesting that pDC are critical for the development of autoimmune skin inflammation in mice

This approach was then used to assess the tape stripping response of lupus-prone NZBxNZW mice. These animals developed chronic skin lesions resembling human cutaneous lupus erythematosus (CLE) distinct from those seen in normal mice. The most likely ligands for TLR7 and TLR9 in injured skin are endogenous nucleic acids released from keratinocytes and other cell types dying as a consequence of mechanical injury or neutrophil cytotoxicity. The authors hypothesize that circulating RNA and DNA act as the endogenous source of the TLR ligands, as are often found as part of the immunocomplexes that are known to accumulate at the dermis-epidermis junction. Ultimately, the basic mechanisms that underpin both acute and chronic lesions are quite similar, and more research is required to understand the self-perpetuating inflammatory loop that is seen in a variety of diseases with interface dermatitis.

One additional feature is clear: The Type-I interferon signature also precedes the involvement of CD8+ T cells (cytotoxic T cells or CTL) that infiltrate the basal epidermis dermis and induce keratinocytic apoptosis. In a variety of ID conditions (see Wenzel and Tüting), interferon-induced protein 10 (IP-10 or CXCL10) is expressed in exactly those areas where CXCR3+ CTLs infiltrate the basal epidermis and induce keratinocytic apoptosis. pDC, then, are uniquely poised to secrete large amounts of interferon in response to this process. Insights into the mechanism of pDC activation, homing and cytokine secretion, may very well help

provide the tools necessary to develop more focused and reliable diagnostics for autoimmune inflammatory skin disorders, such as lichen sclerosis.

## Th1 responses in Lichen Sclerosis

Terlou A, Santeagoets LAM, van der Meijden WI, Heijmans-Antonissen C, Swagemakers CMA, van der Spek PJ, Ewing PC, van Beurden M, Helmerhorst TJM, Blok LJ. 2012. An Autoimmune Phenotype in Vulvar Lichen Sclerosis and Lichen Planus: A Th1 Response and High Levels of MicroRNA-155. *J Invest Dermatol* 132:658-666.

Vulvar lichen sclerosis (LS) and lichen planus (LP) are chronic inflammatory skin disorders of unknown etiology. While it has been suggested that these disorders represent autoimmune conditions, the lack of molecular understanding has prevented the development of targeted therapies. Therefore current therapies such as corticosteroids serve to reduce symptoms, but do not stop disease progression. The study presented by Terlou et al, is aimed at unraveling the mechanisms that contribute to the pathology of vulvar lichen sclerosis and lichen planus by performing genome-wide mRNA profiling on biopsy samples from patients compared to healthy donors. This analysis uncovered that LS and LP were remarkably similar with only approximately 600 genes differentially expressed between the two groups, whereas both LS and LP samples differed from control samples in the expression levels of more than 6,000 genes. Pathway analysis indicated that the majority of the deregulated genes participate in relatively few types of biological functions such as: antigen presentation, cell-mediated immune response, humoral immunity and the general inflammatory response. For instance, both the LS and LP samples showed a marked increase in levels of Th1-associated genes such as IFN $\gamma$ , CXCR3, CXCL9, CXCL10, CXCL11, CCR5, CCL4, and CCL5. This study suggests a lack of pronounced Th17 and Th2 involvement, as key genes that play a role in the differentiation and function of these two T cell subsets were unaltered. Consistent with these molecular changes, increases in infiltrating T cells in the dermis of the patient samples were also observed.

Importantly, Terlou et al. also identified an alteration in miR-155 levels in LS and LP samples relative to the healthy controls. MicroRNA (miR) are a class of non-coding RNAs that serve to regulate gene expression by complementary base-pairing to target mRNA sequences and functioning to reduce protein expression. miRs are thought to have great potential in diagnostics and therapeutics due to their stability and ability to be modulated. Relevant to the study presented by Terlou et al., miR-155 has a well-documented role in regulating immune balance by targeting key chemokines, cytokines, and proteins involved in antibody production and therefore, could prove to be an interesting potential avenue to for the development of novel therapies.


## Topical immunomodulators in Lichen Sclerosis treatment

Kim GW, Park HJ, Kim HS, Kim SH, Ko HC, Kim BS, Kim MB. 2012. Topical tacrolimus ointment for the treatment of lichen sclerosis, comparing genital and extragenital involvement. *J Dermatol*. 2012 39(2):145-50.

Lichen sclerosis is a chronic, inflammatory skin condition that most commonly occurs in adult women, although it may also be seen in men and children. It primarily affects the genital area and around the anus, where it causes persistent itching and soreness. Scarring after inflammation may lead to severe damage by fusion of the vulval lips (labia); narrowing of the vaginal opening; and burying of the clitoris in women and girls, as well as tightening of the foreskin in men and boys, if treatments are not started early. Affected people have an increased risk of genital cancers.

The treatment may be pharmacological or surgical, the choice depending on the extension of the involved area, the histological pattern and the level of functional disease complained by the patient. Surgery is normally a good option for men. Circumcision (removing the foreskin on the penis) is the most widely used therapy for men with lichen sclerosis. The disease usually does not recur. Surgery is normally not a good option for women. When the lichen sclerosis patches are removed from the genitals of women and girls, they usually do recur. Pharmacological treatment includes using very strong cortisone cream or ointment on the skin. However, long-term usage of cortisone causes serious side effect and needs regular medical attention by a doctor.

In this manuscript, the research group evaluates topical tacrolimus ointment for the treatment of lichen sclerosis. Tacrolimus is an immunosuppressive drug that blocks the activation of T-cells. Sixteen patients with active lichen sclerosis (10 with anogenital and 6 with extragenital localization) were recruited and treated topically with tacrolimus ointment twice daily. 90% of patients with anogenital lesions and 16.7% of patients with extragenital lesions showed objective responses to this therapy. More importantly, no significant adverse effects were observed. This study indicates that topical tacrolimus ointment can be used as a safe and effective treatment for genital lichen sclerosis but not extragenital lichen sclerosis. It should also be used for long-term duration to prevent relapse because of the absence of noticeable side effects.



Medical Diagnostic Laboratories, L.L.C.  
2439 Kuser Road  
Hamilton, NJ 08690

A MEMBER OF GENESIS BIOTECHNOLOGY GROUP

Presorted  
First-Class Mail  
U.S. Postage  
PAID  
Trenton, NJ  
Permit 348



► **Research & Development**  
Lichen Sclerosus  
*Continued* ..... pg 2



► **Test Announcement**  
Tests now available in the clinical  
laboratory  
*Full Article* ..... pg 2



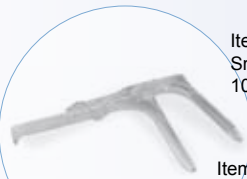► **Journal Watch**  
Summaries of recent topical publications  
in the medical literature  
*Full Article* ..... pgs 5

# The Laboratorian<sup>SM</sup>



## WorldWide Medical Products, Inc.

A MEMBER OF GENESIS BIOTECHNOLOGY GROUP



Item Number - 14001003  
Small Vaginal Speculum, Indiv. Wrapped  
10/pack - \$37.95

Item Number - 14001004  
Medium Vaginal Speculum, Indiv. Wrapped  
10/pack - \$39.95

Item Number - 14001005  
Large Vaginal Speculum, Indiv. Wrapped  
10/pack - \$41.95

Item Number - 14011002  
Exam Table Rolls, Crepe, 21" x 125',  
White 12/case - \$24.92



Item Number - 14011006  
Exam Table Rolls, Smooth, 21" x 125',  
White 10/pack - \$35.76

Item Number - 31031000  
3" Cotton Tipped Applicator  
1000/box - \$3.15



Item Number - 31031001  
6" Cotton Tipped Applicator  
1000/box - \$4.49

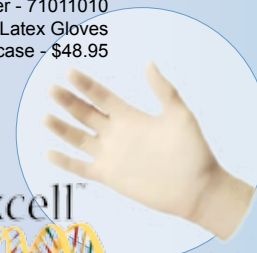
Item Number - 31031005  
5 1/2" Tongue Depressors Sterile  
1000/case - \$32.95

Item Number - 31031006  
6" Tongue Depressors Sterile  
1000/case - \$32.95

Item Number - 71011000  
Powder-Free Nitrile Gloves  
1000/case - \$54.95



Item Number - 71011010  
Powder-Free Latex Gloves  
1000/case - \$48.95



41021159	10x75- Borosilicate Disposable Culture Tubes- 1000/cs	34.50
41021160	12x75- Borosilicate Disposable Culture Tubes- 1000/cs	38.75
41021161	13x100- Borosilicate Disposable Culture Tubes- 1000/cs	49.25
41021164	16x125- Borosilicate Disposable Culture Tubes- 1000/cs	79.50
41021165	16x150- Borosilicate Disposable Culture Tubes- 1000/cs	85.50

866.889.WWMP(9967) • FAX: 609.570.1110 • [WWW.WWMPONLINE.COM](http://WWW.WWMPONLINE.COM)

For information on placing a classified advertisement, please email [sthompson@mdl.com](mailto:sthompson@mdl.com).